

Comparison between Bacterial Cellulose Graft and Temporalis Fascia Graft in Myringoplasty

Mohsen Mahmoud Abd El Raziq¹, Mohamed Osman Abdel-Monem²,
Aya Elsayed Abd El Raziq*¹ and Mostafa Gomaa Sobhy¹

¹ Otorhinolaryngology Department, Faculty of Medicine and ² Botany and Microbiology Department, Faculty of Science, Benha University, Benha, Egypt

*Corresponding author: Aya E. Abd El Raziq, Mobile: (+20) 01099995712,
E-Mail: ayaelsayedelzatahry@gmail.com, ORCID Number: 0009-0005-2745-1041

ABSTRACT

Background: Perforation of the tympanic membrane is a common clinical concern for ENT specialists. They're mostly small to medium. Mini myringoplasty is a less invasive way to repair perforations of this size. **Objective:** The current study's purpose is to compare two grafts in myringoplasty, temporalis fascia and bacterial cellulose according to their results.

Patients and Methods: A non-randomized clinical trial. This study continued from May to November 2022 and included all patients who fulfilled the inclusion and exclusion criteria.

Results: Our study comprised 40 patients, ranging in age from 20 to 50, including 14 men and 26 females. The surgical success rates for the temporalis fascia group were 75%, while those for the bacterial cellulose group were 90%. In the temporalis fascia group, the mean Air Bone (A-B) gap was 21.50 ± 3.28 preoperatively and 13.35 ± 5.93 postoperatively. The surgery took 70.75 ± 5.68 minutes. In the bacterial cellulose group, the mean A-B gap was 22.00 ± 3.40 preoperatively and 10.25 ± 4.41 postoperatively. The surgery took 15.80 ± 2.40 minutes.

Conclusions: Myringoplasty with bacterial cellulose graft is a safe, minimally invasive, effective procedure. There is no need for any harvesting incision. It is a low-cost option, a simple procedure that can be done in an outpatient clinic with just local anesthesia and no hospital stay required. In this study, we have achieved in the bacterial cellulose group a high success rate in healing and hearing results and also significantly less operating time than temporalis fascia graft myringoplasty.

Keywords: Temporalis Fascia, Bacterial cellulose (BC), Myringoplasty.

INTRODUCTION

Various graft materials, such as a vein, concha or tragal cartilage, temporalis fascia and xenograft, are employed for tympanic membrane repair in tympanoplasty. One of these graft materials is temporalis fascia, its most popular because of its accessibility, closeness to the donor site on the surgical field and its high success rate. When it is used as graft in traditional myringoplasty, patients often experience significant improvement in hearing and healing of perforation. However, this approach leaves a visible scar and causes permanent numbness around the ear following surgery [1].

Reperforation of temporalis fascia grafts is common in patients with eustachian dysfunction, disease of the middle ear as adhesive otitis media, and disease in tympanic membrane as atrophic, sclerotic membrane and bilateral or completely perforation in it [2].

Bacterial cellulose is a type of extracellular polymer. It biosynthesized from glucose by bacteria. It has several desirable characteristics due to its physiochemical nature and crystalline nano-fibrillar structure. These characteristics include high chemical purity (i.e., no lignin or hemicellulose), degree of polymerization is 8000, excellent water uptake, high thermal stability [3].

The fermentation of the *Acetobacter xylinum* bacterium would result in the formation of a bacterial cellulose film. They are inert, resistant, and unable to be

dissolved. Despite its potential permeability to liquids and gases, it would be very resistant to tension and stretching. The substance in issue must be safe and sterile [4].

Bacterial cellulose is favored as a graft material because of its excellent qualities, which include strong tensile strength, thermal stability, mechanical strength, and water retention [5]. Recent research has shown that wounds may heal quickly with the help of bacterial cellulose because of its potential to stimulate cellular proliferation and differentiation [6].

Since BC's purification processes are simpler, more cheaper, and environmentally friendly than other plant-based cellulose, it is being evaluated for a wide variety of applications [7]. Preclinical and clinical investigations demonstrated the efficacy of this biomaterial as a mechanical barrier and also as an adjuvant in the management of wounds [8] and ulcerative lesions [9].

The current study purpose is to compare between two grafts, temporalis fascia and bacterial cellulose according to results of them in myringoplasty of small or moderate perforations.

PATENTS and METHODS

This is a non-randomized clinical trial. This study was conducted from May 2022 to November 2022 and all patients who fulfilled the specified inclusion and

exclusion criteria were included.

Inclusion criteria:

1. Ages 20-50 (inclusive).
2. A small perforation in the tympanic membrane (around 3 mm)
3. Perforation in the tympanic membrane (medium size) measuring between 3 and 5 mm in diameter.
4. Tympanic membrane perforation that lasts longer than six months
5. Air bone gap less than 30 decibels.

Exclusion criteria:

1. Prior ear surgery history
2. Cholesteatoma of the middle ear.
3. Large perforation in tympanic membrane (> 5 millimetres).
4. Perforation of the tympanic membrane in both ears
5. Dysfunctional eustachian tube.
6. Systemic illnesses include diabetes, hypertension, and hepatitis.
7. Patients who would not be found throughout the follow-up period.

Preoperative assessment:

History taking

1- Personal history: sex, age, residence, special habits of the patients or their relatives.

2- Present history:

a- Analysis of complaint (hearing loss): Onset - Course - Duration.

b- Nasal problem: such as discharge, obstruction, and nasal allergy.

c- Present history of any ENT symptoms and diseases.

3- Past history:

a- Any systemic diseases and drug intake

b- Past history of other ENT problems or operations.

Examination

1- General examination and vital signs

2- Ear examination: otoscopic and/or microscopic examination.

a- External auditory canal for:

- Anterior hump that leads to narrowing of the canal and difficult insertion of the graft.

- To exclude any mass, foreign body, or impacted wax.

b- Tympanic membrane:

-Exclude any signs of acute inflammation, granulations, and polyps.

-Size and site of the perforation.

c- Middle ear for: cholesteatoma, granulation

tissue, tumor and middle ear infection and discharge.

3-Nasal and nasopharyngeal examination:

To exclude infection, swelling or masses in the nose and skull base area.

Investigations

1. Pure tone audiometry,
2. Tympanometry for evaluation of Eustachian tube function.
3. C.T. of temporal bone.

Surgical procedures:

a. Patient position:

Supine position, face tilted and rotated to the opposite side, and neck is extended.

b. Surgical approach:

In the case of a bacterial cellulose graft, the procedure was performed transcanal via perforation under local anesthesia. For temporalis fascia grafts, a postauricular surgical procedure was made while the patient was under general anesthesia.

c. **Steps of surgery:**

Sterilization:

Common antiseptic precautions were performed.

Anesthesia:

In all cases of bacterial cellulose grafting, local anesthetic was administered by injecting 5 ml of 2% lignocaine with adrenaline [1:100,000] into each of the four quadrants of the external ear canal and behind the ear lobule. All patients undergoing temporalis fascia grafting were under general anesthetic.

Graft harvesting:

Bacterial cellulose graft preparation:

Production took place on Hestrin and Schramm medium. About 50 ml of this medium was used in 100 ml Erlenmeyer flasks for the fermentation process, and the flasks were incubated as a static culture at 28-30 °C for seven days after being inoculated with the contents of one tube of standard inoculums.

To make the standard inoculums, amount of glucose-ethanol acetic medium, about 5, ml was inoculated into a test tube. It was mixed with 1 ml of the tested culture and incubated for three days at 28-30°C, the contents of this tube were used as standard inoculums. After the bacterial cellulose was generated, it was harvested from the growth medium and washed in distilled water. After that, it boiled for 20 minutes at 100±5 °C in a flask containing 4% NaOH to kill any remaining germs.

After the bacterial cellulose was formed (Fig. 1), it was filtered through paper to remove any excess solutions, then transferred to a Petri dish in

an oven-dry and dried for three hours at 45 °C to achieve a dry graft of fine thickness (0.3 millimeter) (Fig. 2).



Figure (1): Wet bacterial cellulose.



Figure (2): Bacterial cellulose after drying

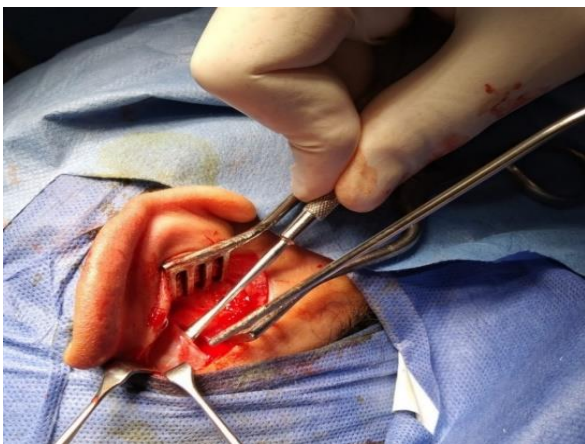


Figure (3): Obtaining of temporalis fascia graft.

Temporalis fascia graft preparation:

Before use, extracted temporalis fascia was freed of muscle fibers (Fig. 3) and allowed to dry for a few minutes (Fig. 4).

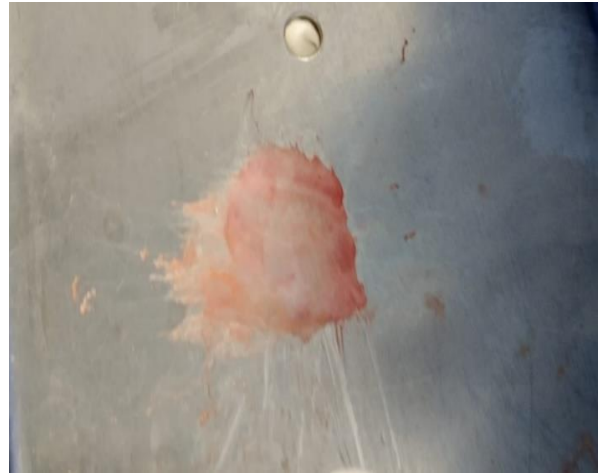

Figure (4): Drying of temporalis fascia graft

Preparing the TM stage:

Trimming the edge of the perforation (Fig. 5), a Rosen needle and a cupped forceps were used to incise and clean the margins of the perforations along the whole circumference. A strip of mucosa was removed from the perforation inner side as well.

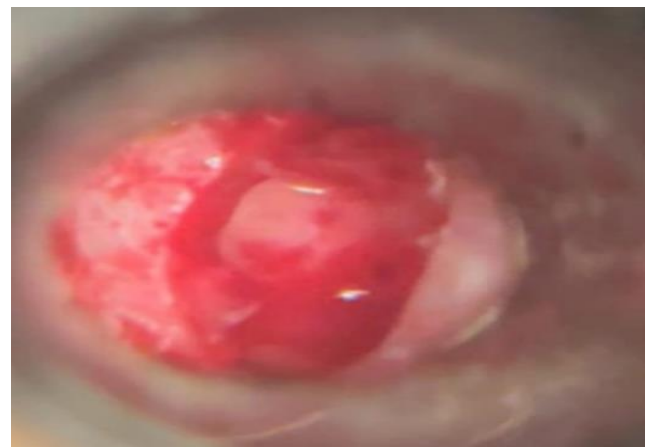


Figure (5): Margin of perforation after trimming.

Placing the graft:

Bacterial cellulose graft:

- All patients got local anaesthetic with a 27G needle containing 2% lidocaine and 1:100,000 epinephrine.
- The surgery was performed using an operating microscope and a permeal approach.

The BC graft was preoperatively shaped to accommodate the perforation size.

- A cupped forceps and Rosen needle were used to incise and renew the perforation edges.
- Afterward, using an overlay grafting approach, BC was positioned over the perforation and laterally to the remaining tympanic membrane.
- The graft stayed in place because of its self-adhesion.
- Non-packing external ear.
- Patients were released after the operation with instructions to avoid blowing their noses or getting water in their ears.
- There was no antibiotics prescribed.

Follow up:

All patients had a microscopic examination of their ears one week, two months, and three months following surgery. The patient was told to contact the clinic if he noticed any discharge from the treated ear or a decline in her hearing, both of which might be signs that the graft had detached from the perforation. A second graft was placed in the same way as the first, with the addition of just mildly injuring or peeling the perforation edge in case the first graft had come detached at a subsequent follow-up appointment. After TM perforation repair, we tested with Pure Tone Audiometry and Air Bone Gap.

Temporalis fascia graft:

General anesthesia was used for all procedures with this method. The skin behind the ear and the meatus were injected with a mixture of 1% xylocaine and 1:100,000 adrenalin. An incision was made slightly

above the pinna and continued around to the mastoid tip, 0.5 cm posterior to the postauricular sulcus, through the skin alone to protect the underlying fascia and periosteum. The temporalis fascia graft was harvested as the superior flap was raised. The temporalis fascia was removed from the muscle and then dried for a few minutes before being used. A sharp, curved needle was used to refresh the tympanic perforation's margin.

A Rossen knife was used to produce a bare surface beneath the perforation's anterior margin.

The tympanomeatal flap was dissected all the way down to the annulus. Using a sickle knife, the posterosuperior tympanomeatal wall was elevated until the original tympanic sulcus was reached. Using a curved needle, the annulus was elevated from bony sulcus, exposing the middle ear.

The auricle and tympanomeatal skin flap were held in place with self-retaining retractors. The continuity and mobility of the osseous chain were evaluated, then packing middle ear with one piece of gel foam. The graft was introduced beneath tympanomeatal flap into the tympanic cavity (Fig. 6). The apex of the manubrium mallei came to rest on top of the graft (underlay technique).

Repositioning of the tympanomeatal flap:

Gel foam pledges were placed over the tympanic sulcus and the external canal to maintain the position of the graft and tympanomeatal flap (Fig. 7). The auditory canal was packed. Vicryl was used to close the periosteal flaps, and stitches were used to close the skin incision.

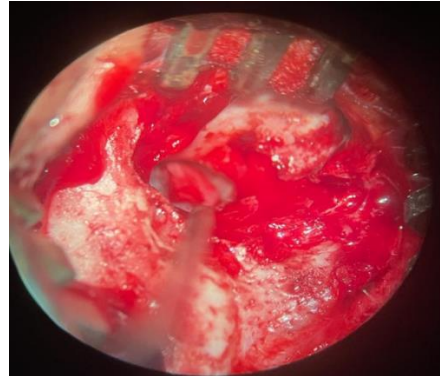
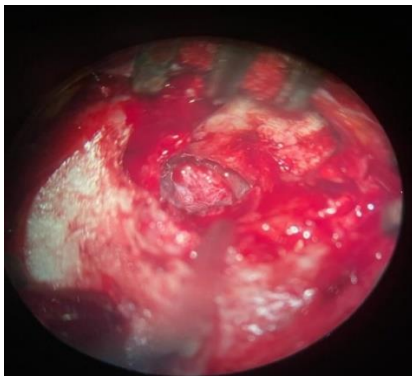


Figure (6): Introduces temporalis fascia graft to tympanic cavity underneath tympanomeatal flap

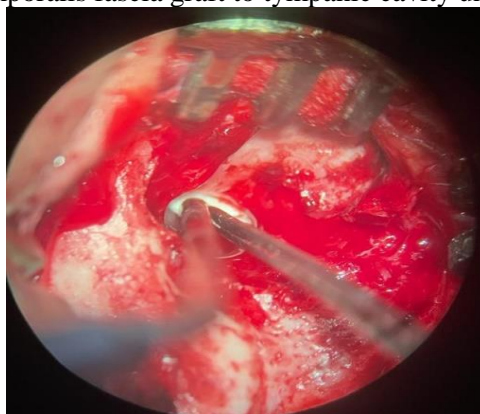


Figure (7): Applying pledges of gel foam over the tympanic sulcus and the external canal.

Postoperative care:

- Postoperatively, the patient was administered an appropriate antibiotic.
- Dressing and sutures (behind the earlobe) were removed after one week.
- If the ear pack became wet it was replaced after 7-10 days. After ten days, the pack was removed and examined under the microscope.
- Gel-foam was left for spontaneous absorption and if it is still present after three weeks, it was removed by mild suction under the microscope.
- Weekly microscopy examinations were performed to detect the graft's success.

Follow up:

- The period of the follow-up was six months. Following information was recorded during follow-up:
 1. Air bone gap.
 2. Pure tone audiometry.
 3. Presence of an infection, granulation tissue, or recurrent perforation.

Ethical considerations:

The study was done after approval from the Ethical Committee in Otorhinolaryngology Department, Benha University. Each patient signed a written informed consent form to agree to participate in the study. Potential risks and benefits were discussed with the patients in details. The

study was conducted out in line with the Helsinki Declaration.

Statistical analysis

The collected data were revised, coded, and tabulated using Statistical Package for the Social Sciences (IBM Corp. Released 2017. IBM SPSS Statistics for Windows, Version 25.0. Armonk, NY: IBM Corp.). Data were presented and suitable analysis was done according to the type of data obtained for each parameter. The data's normality was determined with the use of the Shapiro-Wilk test and histograms. Mean, standard deviation (SD), median, and range were used to summarize quantitative data. Independent and paired student T tests were used to assess the statistical significance of the difference between two study group means and between two periods of the same group, respectively. Qualitative data were presented as frequency and percentage and were compared by the chi-square test and the Fisher exact test; if necessary. In this study, statistical significance was defined as a two-tailed P value ≤ 0.05 .

RESULTS

This study comprised 40 patients, ranging in age from 20 to 50, including 14 men and 26 females. Patients were allocated into two groups, group (A) bacterial cellulose graft and group (B) temporalis fascia group. All patients were followed-up and analyzed statistically. Age and sex were insignificantly different between two groups. Size of perforation and its site showed insignificant difference (Table 1).

Table (1): Baseline characteristics, size of perforation, and site among patients with bacterial cellulose and patients with temporalis fascia

| | Bacterial cellulose (n = 20) | | Temporalis fascia (n = 20) | | Test (p) |
|----------------------------|------------------------------|-------|----------------------------|-------|-----------------------------------|
| | Count of cases | % | Count of cases | % | |
| Sex | | | | | |
| Male | 8 | 40.0% | 6 | 30.0% | Chi-Square=0.440 p-value=0.507 |
| Female | 12 | 60.0% | 14 | 70.0% | |
| Age (years) | | | | | |
| Mean \pm SD. | 30.25 \pm 6.37 | | 33.40 \pm 7.44 | | Student-t=1.438 p-value=0.159 |
| Median (Range) | 30.0 (20.0 – 40.0) | | 35.0 (20.0 – 45.0) | | |
| Size of perforation | | | | | |
| Small size | 12 | 60.0% | 12 | 60.0% | Chi-Square=0.0 p-value=1.000 |
| Medium size | 8 | 40.0% | 8 | 40.0% | |
| Site of perforation | | | | | |
| Right | 14 | 70.0% | 12 | 60.0% | Chi-Square=0.440 p-value=0.507 |
| Left | 6 | 30.0% | 8 | 40.0% | |

SD: Standard deviation, Range: Min. – Max

Regarding the difference between the two groups in duration of operation, bacterial cellulose group had marked shorter time than temporalis fascia group (Fig. 8).

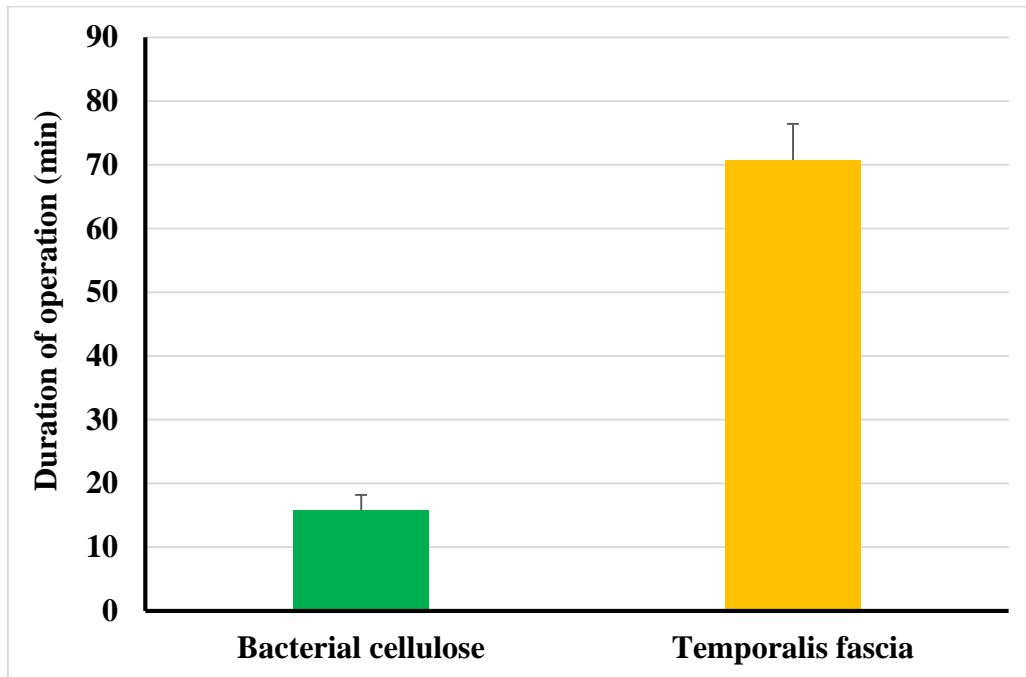


Figure (8): Column chart for comparison of duration of operation among patients with bacterial cellulose and patients with temporalis fascia

Regarding the outcome among patients with bacterial cellulose and patients with temporalis fascia, bacterial cellulose group had insignificantly higher success rate (Fig. 9).

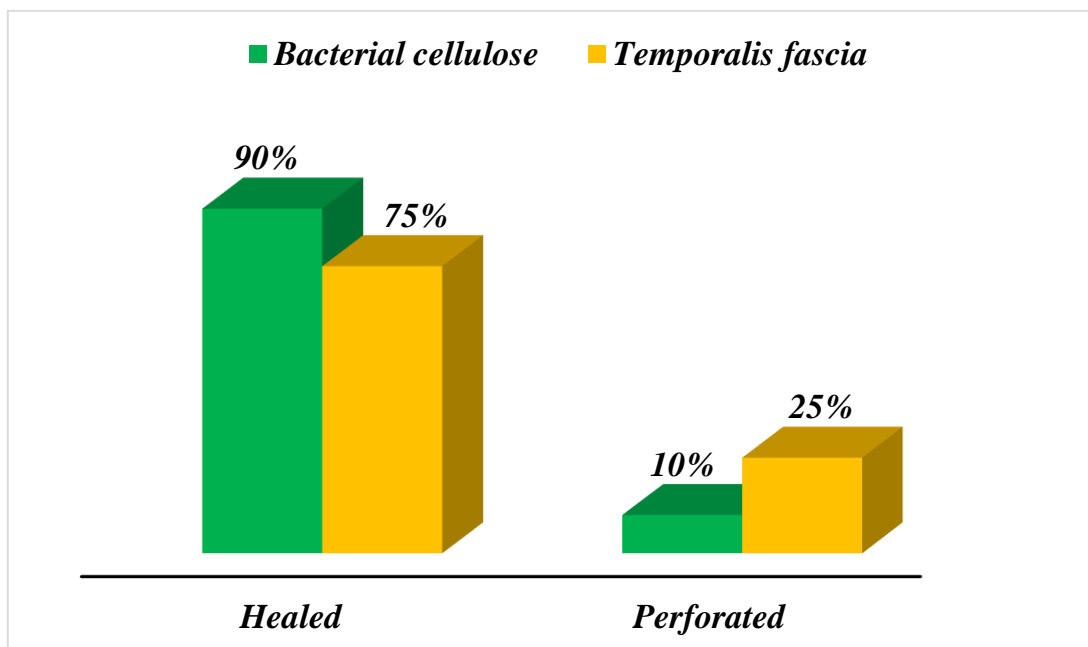


Figure (9): Column chart for comparison of healing among patients with bacterial cellulose and patients with temporalis fascia

There was no significant difference regarding the presence of postoperative tinnitus between the studied groups (Fig. 10).

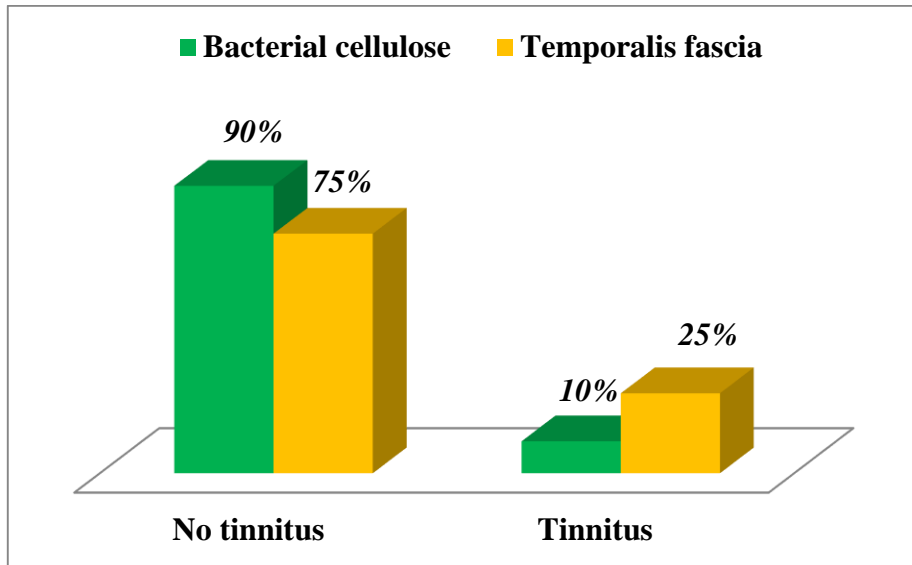


Figure (10): Column chart for comparison of tinnitus among patients with bacterial cellulose and patients with temporalis fascia.

Regarding the difference in air-bone gap, postoperatively bacterial cellulose graft had significantly decreased gap compared to temporalis fascia graft group. Both groups showed significant improvement postoperatively (Fig. 11).

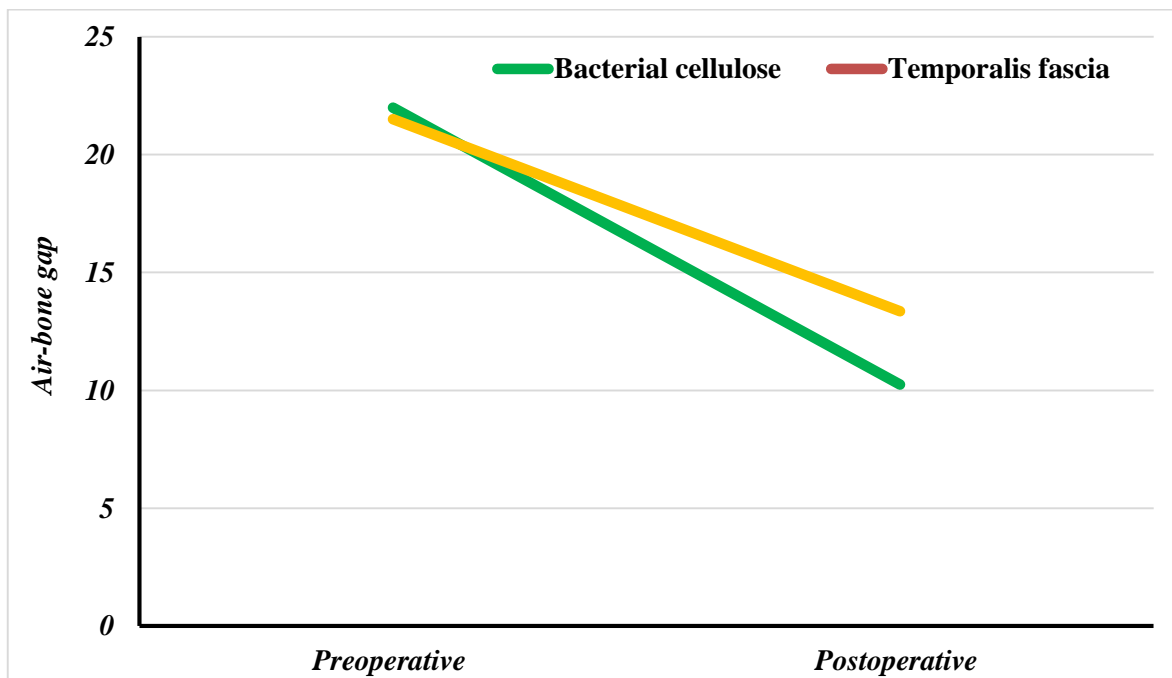


Figure (11): Line chart for comparison of air-bone gap among patients with bacterial cellulose and patients with temporalis fascia

In this study tympanic membrane perforation before using any graft (Fig. 12), healing of perforation after using bacterial cellulose graft (Fig. 13), and another case after using temporalis fascia graft (Fig. 14).

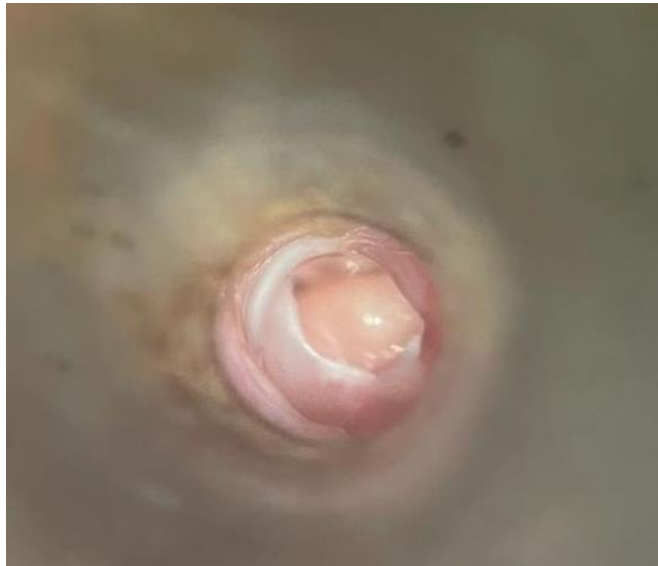


Figure (12): Tympanic membrane perforation

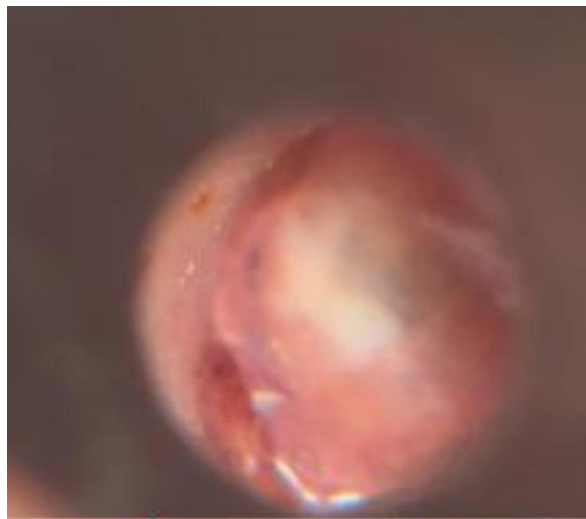
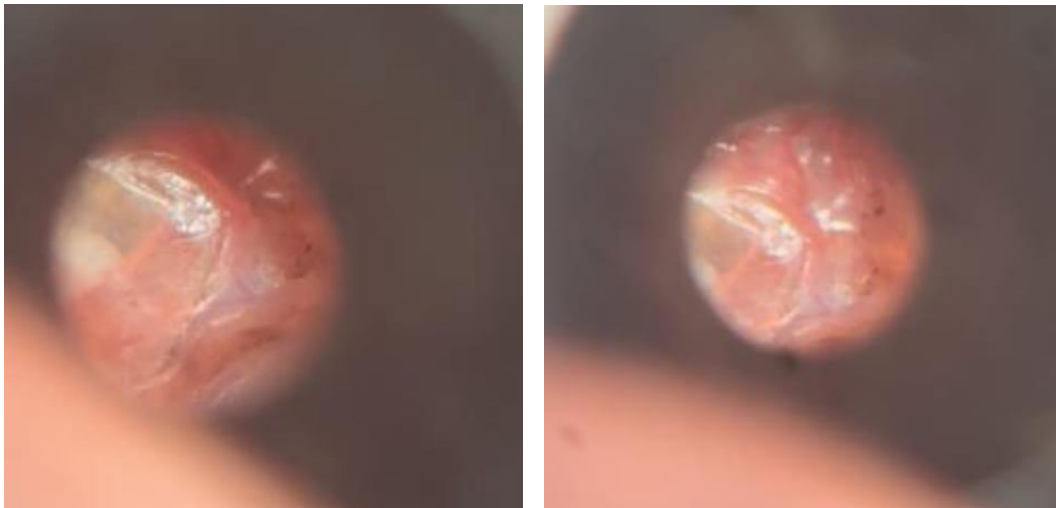


Figure (13): Tympanic membrane perforation healing by bacterial cellulose graft

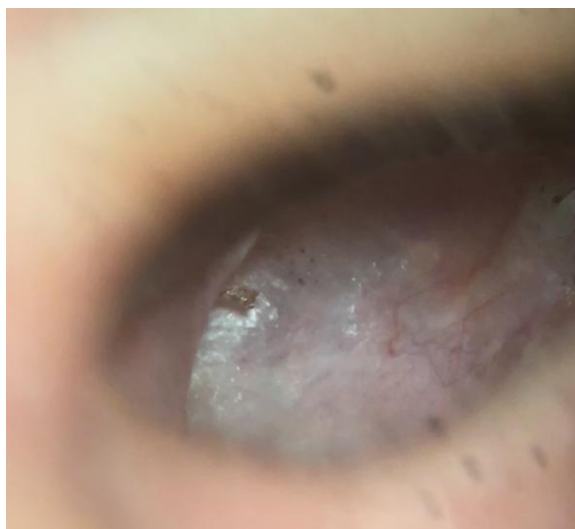

Figure (14): Tympanic membrane perforation healing by temporalis fascia graft.

DISCUSSION

Perforation of tympanic membrane is one of the most observed clinical conditions in ENT practice. Causes include acute or chronic otitis media (COM), trauma, and other reasons. It is necessary to repair this perforation to restore hearing and prevent further infections. Myringoplasty may be performed using a broad variety of graft materials such as vein, fascia, skin, and cartilage grafts, while the ossicular chain is still intact [10].

Reconstructive myringoplasty of the TM is performed on individuals with dry central TM perforation to improve HL and prevent recurrent ear discharge [11,12]. Some variables that may influence the operation's outcome include age of patient, the size of perforation and its site, the health of the mucosa of middle ear, the functionality of eustachian tube, surgeon's level of expertise and the graft kind utilized [13].

This research did not include children because of the persistent belief that this age group has a high failure rate owing to the cases of dysfunctional eustachian tube, secretory otitis media, and problems in caring for patients [14]. Multiple coexisting medical conditions, such as hypertension, diabetes mellitus, sensory neural hearing loss, and presbycusis, excluded elderly people from being involved with the research.

The current study comprised patients with mild to moderate central perforations. Larger perforation has been associated with a high failure rate (6.5–20%) regardless of the grafting material utilized [15]. The size of perforation was not proven to be a significant predictor of effective myringoplasty statistically, according to a study by **Wasson et al.** [16]. Many studies [17-19] found that perforation size affected success rates, whereas others [20,21] found no such relationship.

To prevent graft failure due to infection, the researchers preferred using inactive ears in the trial.

Studies showed that preoperative dry intervals had no effect on operation outcomes [19].

Patients with mild or moderate size safe perforations were included in this research, in which temporalis fascia and bacterial cellulose graft myringoplasty were compared. The temporalis fascia has a similar thickness to the normal tympanic membrane and develops embryologically from mesoderm, just like the normal tympanic membrane [22]. It also has the advantages of being accessible through a single incision and having a low basal metabolic rate. In such cases, the perforation may fail to close because of atrophy and vascularization of the temporalis fascia, which may cause posterior shrinkage or sinking in the middle ear [23].

In this study we did myringoplasty with temporalis fascia graft in 20 cases under general anesthesia. The success rate was 75% regarding graft uptake, The mean of the A-B gap was 21.50 ± 3.28 preoperatively and 13.35 ± 5.93 postoperatively. Duration of surgery was 70.75 ± 5.68 minutes.

These results we achieved was like many studies:

Uptake of temporalis fascia grafts was reported to be 80% in a previous research [24]. The average increase in temporalis fascia hearing was 09.5 dB. According to another research [25], the success percentage of closing tympanic membrane perforations was 83.3% in the temporalis fascia group. Air-bone gap before surgery was 20.7 5.4 dB, and after it was 11.5 5.4 dB. The operation lasted 61.5 6.0 minutes.

Overall, 82% of grafts integrated during fascia tympanoplasty, as indicated by one more research [2].

Myringoplasty performed under local anesthesia is a less expensive, less time-consuming, and less invasive alternative to traditional myringoplasty [26].

Bacterial cellulose has been proven to have excellent wound healing properties due to its ability to

stimulate cellular proliferation and differentiation, which accelerates the healing process [6].

In this study we did myringoplasty with bacterial cellulose graft in 20 cases under local anesthesia. The success rate was 90% regarding graft uptake.

The mean of the A-B gap was 22.00 ± 3.40 preoperatively and 10.25 ± 4.41 postoperatively. This means that there was a marked improvement in the hearing level in this group. Duration of surgery was 15.80 ± 2.40 minutes.

These results we achieved was like many studies:

Complete perforation coverage was achieved using bacterial cellulose myringoplasty in 13 of 16 ears (81.3%) in a previous research [27], but retraction occurred within six months in two of these ears. Three ears (18.8%) had persistent perforation one month after surgery. The air-bone gap was 9.25 dB before surgery and 5.63 dB after.

Another research [28], found that using bacterial cellulose graft had a 90% success rate. Fourteen patients with mild perforations were completely healed, while four with moderate perforations were 66.7% complete. The mean Duration of a surgery was 14.06 ± 5.23 minutes.

A bacterial cellulose graft was successful in repairing small perforation of tympanic membrane in 20 patients and repairing moderate perforations in 17 patients by percentage (100%) and (85%) respectively, according to one research [29]. There was a mean operating time of 15.01 ± 0.46 min. The air-bone gap before and after operation for successful patients decreased from 25.25 ± 0.41 dB to 6.68 ± 0.29 dB.

CONCLUSIONS

Myringoplasty with a bacterial cellulose graft is a low-risk, beneficial option for restoring hearing loss. No incision is required to perform the produce. A local anesthetic and an outpatient clinic make this a low-cost choice with little risk.

There was a significant decrease in surgical time compared to temporalis fascia graft myringoplasty, and the healing and hearing outcomes after tympanic membrane perforation repair were better in the bacterial cellulose group.

Financial support and sponsorship: Nil

Conflict of Interest: Nil.

REFERENCES

1. **Ayache S (2013):** Cartilaginous myringoplasty: the endoscopic transcanal procedure. *European Archives of Oto-Rhino-Laryngology*, 270(3): 853-860.
2. **Jalali M , Motasaddi M, Kouhi A, et al. (2017):** Comparison of cartilage with temporalis fascia tympanoplasty: a meta-analysis of comparative studies. *The Laryngoscope*, 127(9): 2139-2148.
3. **Singhsa P, Narain R, Manuspiya H (2018):** Physical structure variations of bacterial cellulose produced by

- different *Komagataeibacter xylinus* strains and carbon sources in static and agitated conditions. *Cellulose*, 25(3): 1571-1581.
4. **Costa H, Souza F (2005):** Avaliação da regeneração tecidual da pele de porco submetida à lesão térmica seguida de colocação de Biotissue. *ACTA ORL.*, 23(3): 23-7.
5. **Klemm D, Kramer F, Moritz S et al. (2011):** Nanocelluloses: a new family of nature-based materials. *Angewandte Chemie International Edition*, 50(24): 5438-5466.
6. **Sajjad W, Khan T, Ul-Islam M et al. (2019):** Development of modified montmorillonite-bacterial cellulose nanocomposites as a novel substitute for burn skin and tissue regeneration. *Carbohydrate Polymers*, 206: 548-556.
7. **Cacicedo M, Castro M, Servetas I et al. (2016):** Progress in bacterial cellulose matrices for biotechnological applications. *Bioresource Technology*, 213: 172-180.
8. **Martins A, Lima S, Araujo L et al. (2013):** A wet dressing for hypospadias surgery. *International Braz. J. Urol.*, 39: 408-413.
9. **Teixeira F, Pereira M, Ferreira N et al (2014):** Spongy film of cellulosic polysaccharide as a dressing for aphthous stomatitis treatment in rabbits. *Acta Cirúrgica Brasileira*, 29: 231-236.
10. **Santhanakrishnan K, Bhat P (2018):** A comparative study of the outcomes of temporalis fascia graft versus tragal perichondrium graft in type I tympanoplasty in our experience. *Int. J. Otorhinolaryngol Head Neck Surg.*, 4(1): 60-62.
11. **Al-Khtoum N, Hiari M (2009):** Myringoplasty in children: retrospective analysis of 35 cases. *Brazilian Journal of Otorhinolaryngology*, 75: 371-374.
12. **Akayleh R, Alroosan M (2013):** The surgical outcome of myringoplasty in adults in the Royal Medical Services Amman-Jordan. *Khartoum Medical Journal*, 5(3): 420-423.
13. **Spiegel J, Kessler J (2005):** Tympanic membrane perforation repair with acellular porcine submucosa. *Otology and Neurotology*, 26(4): 563-566.
14. **Caylan R, Titiz A, Falcioni M et al. (1998):** Myringoplasty in children: factors influencing surgical outcome. *Otolaryngology—Head and Neck Surgery*, 118(5): 709-713.
15. **Salviz M, Bayram O, Bayram A et al. (2015):** Prognostic factors in type I tympanoplasty. *Auris Nasus Larynx*, 42(1): 20-23.
16. **Wasson J, Papadimitriou C, Pau H (2009):** Myringoplasty: impact of perforation size on closure and audiological improvement. *The Journal of Laryngology and Otology*, 123(9): 973-977.
17. **Das A, Sen B, Ghosh D et al. (2015):** Myringoplasty: impact of size and site of perforation on the success rate. *Indian Journal of Otolaryngology and Head and Neck Surgery*, 67: 185-189.
18. **Jurado F, Gil J, Secall M et al. (2009):** Myringoplasty: auditory follow-up and study of prognostic factors. *Acta Otorrinolaringologica (English Edition)*, 60(3): 169-175.
19. **Shankar R, Virk R, Gupta K, Gupta A et al. (2015):** Evaluation and comparison of type I tympanoplasty efficacy and histopathological changes to the tympanic membrane in dry and wet ear: a prospective study. *The*

- Journal of Laryngology and Otology, 129(10): 945-949.
20. **Lima J, Marone S, Martucci O et al. (2011):** Evaluation of the organic and functional results of tympanoplasties through a retro-auricular approach at a medical residency unit. Brazilian journal of otorhinolaryngology, 77: 229-236.
 21. **Rondini-Gilli E, Mosnier I, Gouin J et al. (2001):** Les greffes tympaniques: techniques chirurgicales et résultats. A propos de 260 cas. In Annales d'oto-laryngologie et de chirurgie cervico-faciale, 118: 67-73.
 22. **Vaidya S, Sharma H (2012):** Cartilage tympanoplasty for management of TM perforation: review of literature. World Artic Ear Nose Throat, 5: 1-7.
 23. **Dabholkar J, Vora K, Sikdar A (2007):** Comparative study of underlay tympanoplasty with temporalis fascia and tragal perichondrium. Indian Journal of Otolaryngology and Head and Neck Surgery, 59: 116-119.
 24. **Kumar R, Suman R, Garje Y, Rao S (2014):** Comparative study of underlay tympanoplasty with temporalis fascia and tragal perichondrium. J. Dent. Med. Sci., 13: 89-98.
 25. **Gozele M, Sahin A (2021):** Comparison of temporalis fascia and transcanal composite chondroperichondrial tympanoplasty techniques. Ear, Nose and Throat Journal, 100(3): 192-195.
 26. **Landsberg R, Fishman G, DeRowe A et al. (2006):** Fat graft myringoplasty: results of a long-term follow-up. Journal of otolaryngology, 35(1): 633-639.
 27. **Biskin S, Damar M, Oktem S et al. (2016):** A new graft material for myringoplasty: bacterial cellulose. European Archives of Oto-Rhino-Laryngology, 273: 3561-3565.
 28. **Silveira A, Pinto M, Caldas S et al. (2016):** Treatment of tympanic membrane perforation using bacterial cellulose: a randomized controlled trial. Brazilian Journal of Otorhinolaryngology, 82: 203-208.
 29. **Mandour Y, Mohammed S, Menem M (2019):** Bacterial cellulose graft versus fat graft in closure of tympanic membrane perforation. American Journal of Otolaryngology, 40(2): 168-172.